



### Wagner Retrograde grafting

?



François M Kelberine M.D  
Aix-en-Provence, France

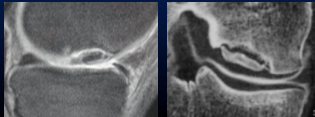


### Case

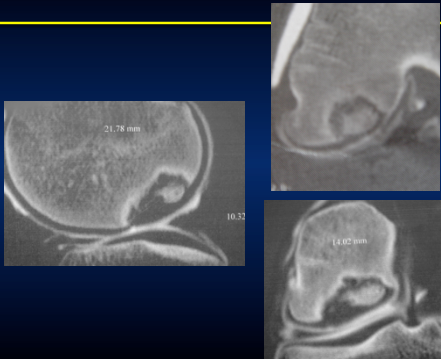
- ✓ Male 16yo soccer
- ✓ Formation center / club pro
- ✓ Swelling w/o locking, slight pain
- ✓ Bilateral flexum 3°
- ✓ Varus alignment

### What is the best imaging to check OCD?

1. X rays (AP, lateral, schuss, long axis)
2. MRI with IV gadolinium
3. Arthro CT scan



### Large & complex OCD

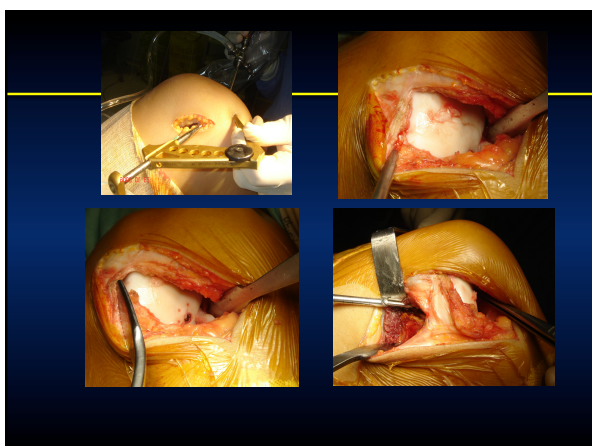
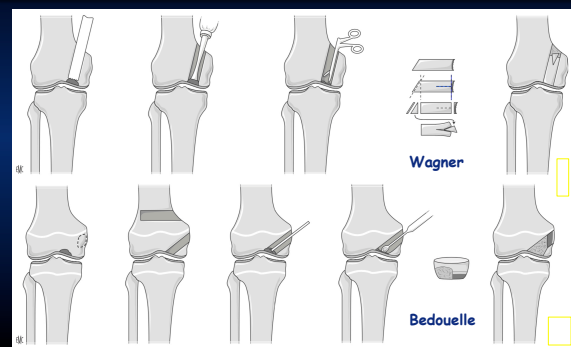


### Treatment options

1. Bone fragment fixation
2. Mosaicplasty
3. Massive allograft
4. HTO
5. ACI
6. Wagner's method graft



### Retrograde Bone Grafting



- ✓ Return to full sport @ 10 mths
- ✓ Arthroscopic screw removal
- ✓ Soften condyle without lesion

